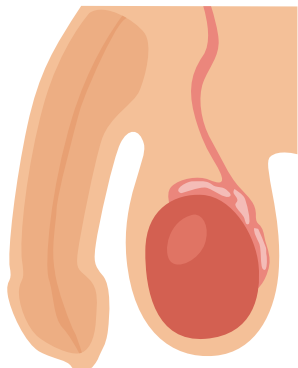
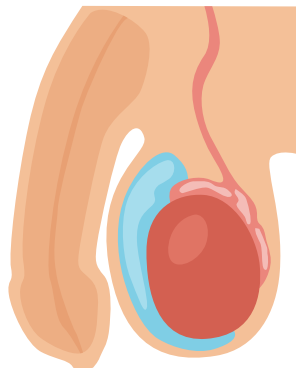


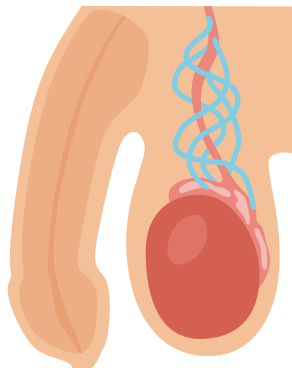
TESTICULAR DISEASE



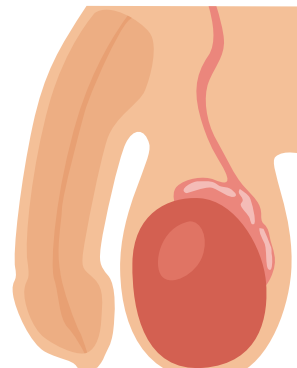
NORMAL



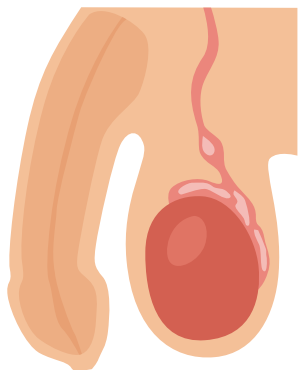
HYDROCELE



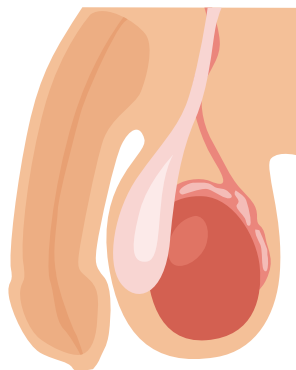
VARICOCELE



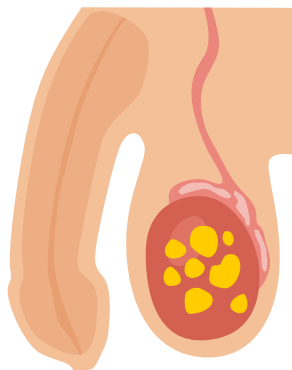
ORCHITIS



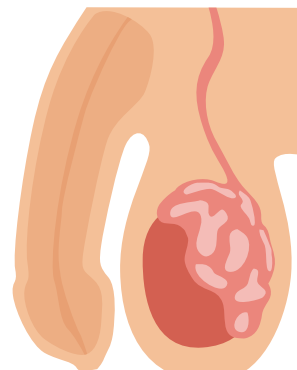
EPIDIDYMAL CYST



HERINIA



TESTICULAR TUMOR



EPIDIDYMITIS